

DIAGNOSIS AND ASSESSMENT OF PECTORALIS MAJOR RUPTURE BY DYNAMOMETRY

B. W. SCOTT, W. A. WALLACE, M. A. J. BARTON

From Queen's Medical Centre, Nottingham

Four patients with pectoralis major ruptures underwent clinical and dynamometric assessment and one patient underwent late surgical repair. The operation is described. Dynamometry proved a useful and objective method of estimating the loss of strength and indicating patients who might benefit from surgical repair.

Four men with pectoralis major muscle rupture, all of whom presented late (9 to 48 months) to the senior author (WAW) had the following clinical features (Fig. 1): abnormal contour of the anterior axillary fold; abnormal appearance of the belly of the pectoralis major muscle; a subcutaneous band passing from the fascia over pectoralis major into the upper arm; palpable loss of thickness of the anterior axillary fold.

The indications for surgical repair of rupture of this

tendon have never been defined. We employed dynamometry to measure directly the strength deficit and to select patients for surgical repair.

PATIENTS AND METHODS

The four men were aged 21 to 49 years and had all sustained pectoralis major ruptures during extreme physical exertion. Despite the characteristic signs noted above, no weakness could be detected by clinical examination. In all four cases there was complete, distal rupture of the sternocostal head of the muscle.

The three planes in which pectoralis major acts are

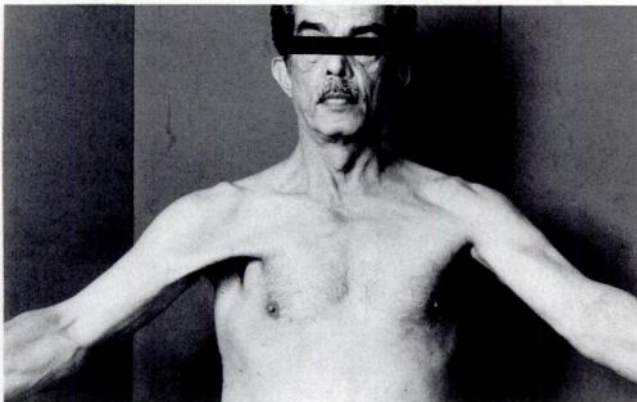


Fig. 1

The visible deformity after pectoralis major rupture on the right. Note the abnormal contour of the right anterior axillary fold and the typical appearance of a subcutaneous band extending into the upper arm.

B. W. Scott, FRCS, Orthopaedic Registrar
East Birmingham Hospital, Bordesley Green East, Birmingham B9
5ST, England.

W. A. Wallace, FRCS Ed, FRCS Ed(Orth), Professor of Orthopaedic
and Accident Surgery

M. A. J. Barton, MSCP, Research Physiotherapist
Queen's Medical Centre, Nottingham NG7 2UH, England.

Correspondence should be sent to Mr B. W. Scott at 2 St Margaret's
Drive, Roundhay, Leeds 8, West Yorkshire, England.

© 1992 British Editorial Society of Bone and Joint Surgery
0301-620X/92/1256 \$2.00

J Bone Joint Surg [Br] 1992; 74-B: 111-13.

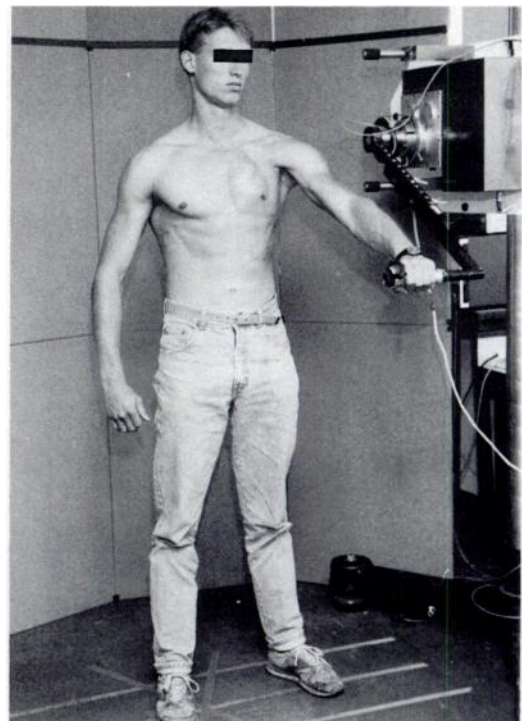


Fig. 2

Patient (case 2) being tested on a dynamometer.

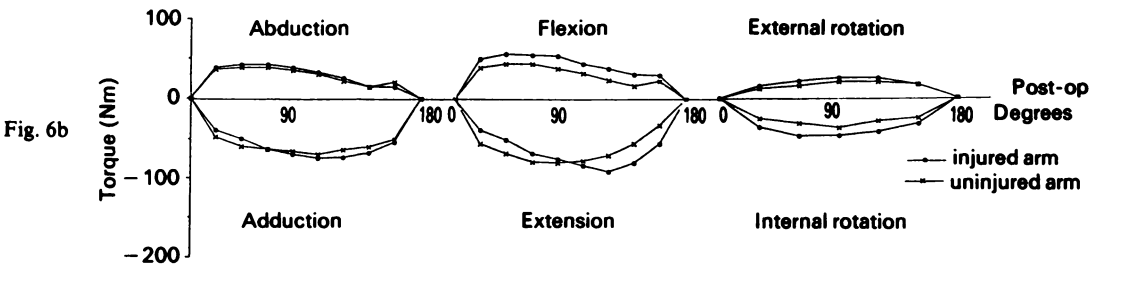
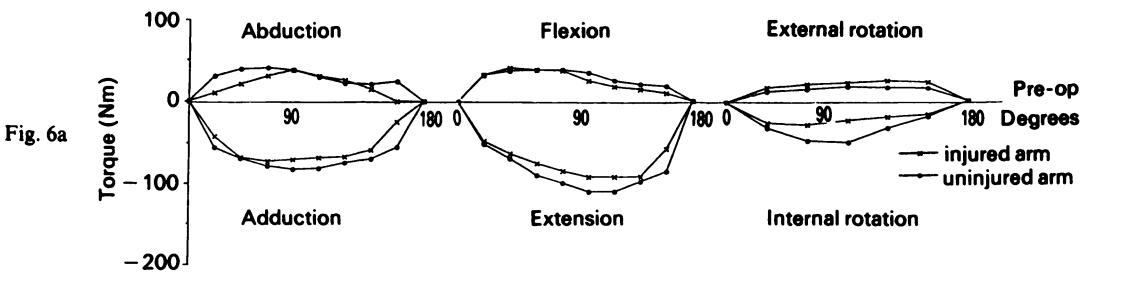
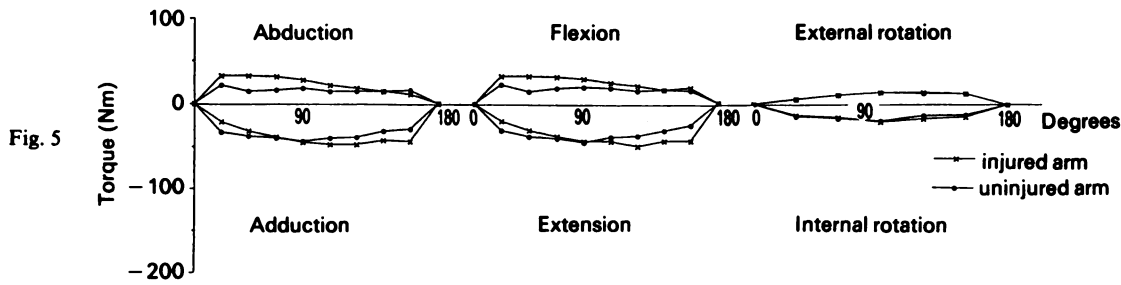
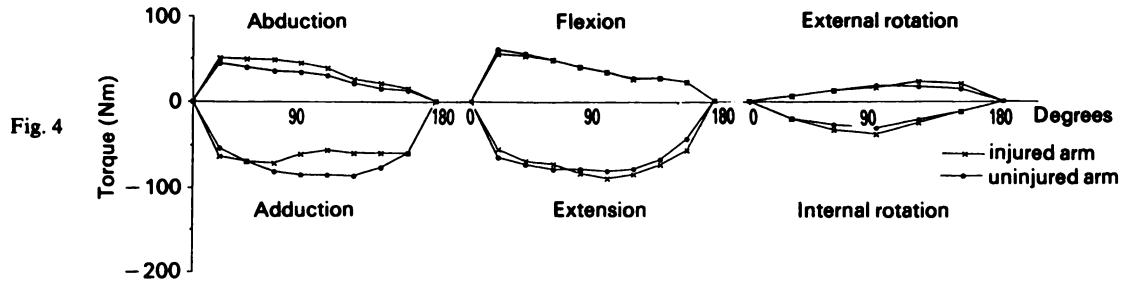
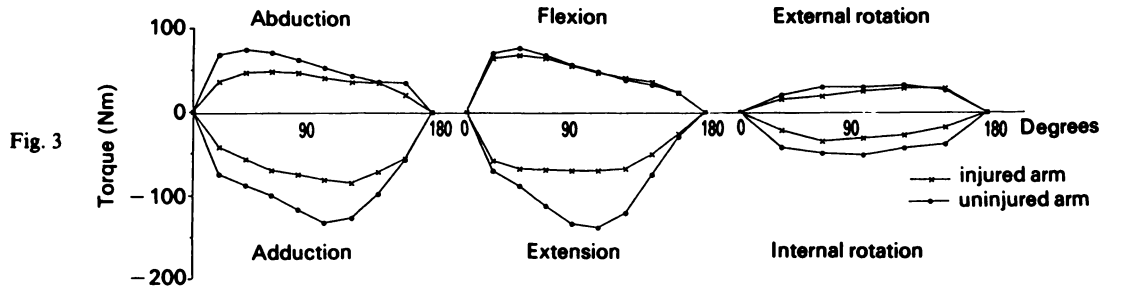


Figure 3 - Dynamometry results, case 1. Rupture of left pectoralis major (dominant). Figure 4 - Dynamometry results, case 2. Rupture of left pectoralis major (non-dominant). Figure 5 - Dynamometry results, case 3. Rupture of right pectoralis major (dominant). Figure 6 - Dynamometry results, case 4; a) before operation and b) after repair of the ruptured left pectoralis major (non-dominant).

adduction, extension and internal rotation. The power of each of these movements was measured using a custom-built dynamometer for adduction and extension (Fig. 2) and a Cybex 2 dynamometer for internal rotation. The patients were shown how to use the apparatus with one or two trial runs. The mean result of three definitive runs was taken as the measure of strength in each plane. The strength of the muscle on the uninjured side was used as the control. Previous work in this department has shown that the dominant arm is usually, but not always, slightly the stronger.

SURGICAL TECHNIQUE

In the one case treated surgically, the axilla was explored through a deltopectoral incision. The tendon of the sternocostal portion of the muscle was found avulsed from its humeral insertion. The tendon was dissected free from the overlying fascia to which it was densely adherent and was sutured to the humerus using drill holes. The shoulder was immobilised in internal rotation for six weeks in a sling, followed by a course of physiotherapy.

RESULTS OF DYNAMOMETRY

In Figures 3 to 6, the strength of adduction, extension and internal rotation for each patient is shown below the horizontal axis.

Patient 1 (Fig. 3) demonstrated the greatest difference between the normal and the injured shoulder. He was the strongest man in the group and the dynamometric findings correlated well with his complaint of shoulder weakness only on the most extreme exertion.

Patient 2 (Fig. 4) had clinically insignificant weakness in adduction, but otherwise the strength of the two shoulders was similar.

Patient 3 (Fig. 5) was the oldest in the group and also had the weakest muscles. He complained of disabling weakness in the injured shoulder, but dynamometry revealed no asymmetry.

Patient 4 demonstrated weakness in all planes of movement, especially internal rotation (Fig. 6a). He underwent surgical repair of the ruptured muscle and nine months later he was symptomatically improved. Dynamometry showed improved strength of internal rotation (Fig. 6b).

DISCUSSION

Although seldom described in standard textbooks, there have been many case reports of rupture of the pectoralis major tendon (Lindenbaum 1975; Tietjen 1980; Orava et al 1984). It has only been reported in men and occurs mainly in athletes and heavy manual workers. McEntire, Hess and Coleman (1972) reviewed the literature to

establish whether surgical repair was useful. They found that 75% of patients had a good or excellent result independently of whether they were treated surgically or conservatively, though the proportion of excellent results was higher in those surgically repaired. Early surgery was recommended for distal injuries as late repair was technically difficult.

The indication for surgery in our patient was weakness in the planes of action of pectoralis major causing disability, and we used dynamometry to quantify the loss of power objectively. The patient's job as a textile worker entailed throwing heavy lengths of fabric which required powerful rotation at the shoulder. Although the absolute increase in strength after repair was not dramatic the relative increase was significant and consistent with the symptomatic improvement.

The preservation of shoulder strength despite rupture of so substantial a muscle as pectoralis major may be explained by the compensatory action of other muscles such as latissimus dorsi and deltoid. It is therefore possible that postoperative physiotherapy was responsible for the increase in power rather than the operative repair though the selective nature of the improvement and the failure of pre-operative physiotherapy make this unlikely.

In another patient (case 3), dynamometry showed that the injured shoulder was stronger than the normal one and no surgical treatment was offered. The patient was involved in litigation and in this context dynamometry can be especially useful.

Dynamometry was also useful in case 1, in which there was a substantial deficit in strength. This had been masked on clinical testing because of the great strength of the patient's other muscles. He fulfilled our criteria for surgery because relative weakness prevented him from returning to competitive sports, but he declined an operation.

Conclusions. We recommend initially conservative treatment for pectoralis major rupture. If symptoms of weakness persist then dynamometry is helpful in the assessment and in the selection of patients suitable for late repair. We did not find the operation unduly difficult and in our one case the result was gratifying.

No benefits in any form have been received or will be received from a commercial party related directly or indirectly to the subject of this article.

REFERENCES

- Lindenbaum BL. Delayed repair of a ruptured pectoralis major muscle. *Clin Orthop* 1975; 109:120-1.
- McEntire JE, Hess WE, Coleman SS. Rupture of the pectoralis major muscle: a report of eleven injuries and review of fifty six. *J Bone Joint Surg [Am]* 1972; 54-A:1040-6.
- Orava S, Sorasto A, Aalto K, Kvist H. Total rupture of pectoralis major muscle in athletes. *Int J Sports Med* 1984; 5:272-4.
- Tietjen R. Closed injuries of the pectoralis major muscle. *J Trauma* 1980; 20:262-4.